

**Bisphosphonate-associated osteonecrosis of the jaws: A review of current knowledge**

MICHAEL R. MARKIEWICZ, JOSEPH E. MARGARONE, III, JOHN H. CAMPBELL and ALFREDO AGUIRRE

*J Am Dent Assoc* 2005;136;1669-1674

---

*The following resources related to this article are available online at [jada.ada.org](http://jada.ada.org) ( this information is current as of October 30, 2008 ):*

**Updated information and services** including high-resolution figures, can be found in the online version of this article at:

<http://jada.ada.org/cgi/content/full/136/12/1669>

This article appears in the following **subject collections**:

Endodontics <http://jada.ada.org/cgi/collection/endodontics>

Information about obtaining **reprints** of this article or about permission to reproduce this article in whole or in part can be found at:

<http://www.ada.org/prof/resources/pubs/jada/permissions.asp>

## CASE REPORT

# Bisphosphonate-associated osteonecrosis of the jaws

A review of current knowledge

MICHAEL R. MARKIEWICZ, B.S.; JOSEPH E. MARGARONE III, D.D.S.; JOHN H. CAMPBELL, D.D.S., M.S.; ALFREDO AGUIRRE, D.D.S., M.S.

**I**ncreasing numbers of patients seeking dental care are receiving bisphosphonate drug therapy. This class of medications is composed of pyrophosphate analogues whose general effects include reduction in bone resorption and turnover. They are used commonly for several medical purposes, including prevention and treatment of bone metastases associated with cancer,<sup>1-5</sup> treatment of increased blood calcium

levels associated with malignant disease, treatment of symptomatic Paget's disease of bone, treatment of avascular necrosis of bone, and prevention and treatment of osteoporosis.<sup>6</sup>

Recent reports have documented necrosis of the jaws associated with the use of bisphosphonates, especially when administered intravenously on a long-term basis.<sup>7-18</sup> Although this condition can be seen in the maxilla as well as in the mandible, the literature reports a slightly higher rate in the mandible.<sup>10</sup> It is important to realize that this is a new clinical entity, and new cases are being

reported daily. Therefore, epidemiologic data, such as prevalence and predominance, are insufficient to report at this time.

We report a case of a patient with osteonecrosis of the jaw associated with bisphosphonate therapy. We also make recommendations for the dental treatment

**Background.** Increasing numbers of dental patients are taking bisphosphonate medications for a variety of indications. These drugs may be associated with poor healing, spontaneous intraoral ulceration and bone necrosis in the oral and maxillofacial region.

**Case Description.** The authors describe a case of osteonecrosis of the jaws in a patient receiving long-term bisphosphonate therapy for cancer. They offer recommendations for management and prevention of oral complications.

**Conclusion and Clinical Implications.** It is important that clinicians are aware of the association between bisphosphonate treatment and delayed wound healing and osteonecrosis of the jaws. They should consider referring patients in this population to specialists for even the most routine oral surgery. Clinicians should perform a thorough oral examination in patients before they begin any chemotherapy regimen.

**Key Words.** Bisphosphonates; osteonecrosis; oral surgery; mandible and maxilla; cancer metastasis; oral complications.

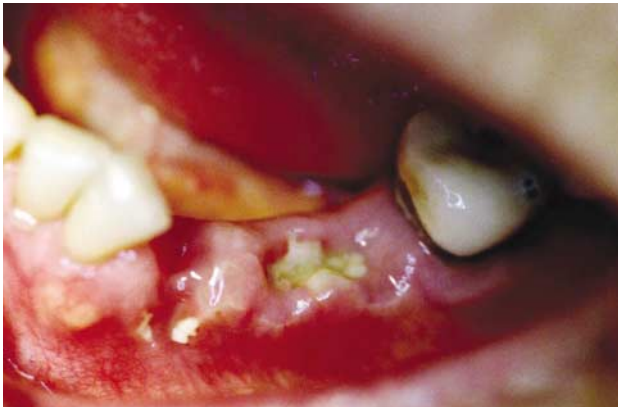of patients receiving long-term bisphosphonate therapy.

## CASE REPORT

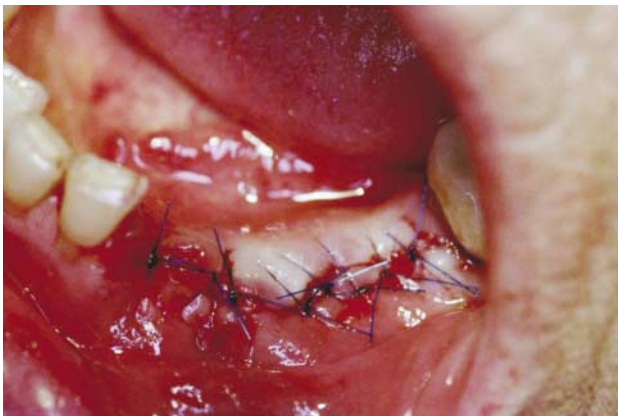A 79-year-old woman was referred to our office by her general dentist for evaluation of a lesion in her left mandible. The patient reported the presence of nonhealing extraction sites after undergoing extraction of an unrestorable tooth no. 20 by her general dentist five months before her initial visit with us. In addition, teeth nos. 21 and 22 had been extracted by her previous oral surgeon four months before her initial visit with us. Teeth nos. 21 and 22 had been extracted because of their involvement with surrounding necrotic tissues. Both surgeries were carried out without flap reflection or primary closure.

The patient's medical records described abscesses associated with teeth

**Clinicians need to be aware of the association between bisphosphonate treatment and delayed wound healing and osteonecrosis of the jaws.**



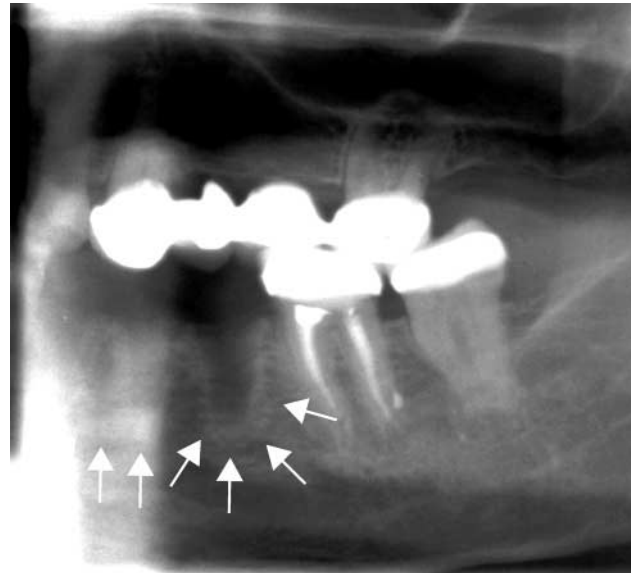
**Figure 1.** Clinical photograph of the nonhealing extraction sites of teeth nos. 20, 21 and 22 five months after their removal showing necrosis of the alveolar bone and surrounding tissue.



**Figure 3.** Postsurgical photograph after débridement of necrosed soft and hard tissue in the extraction site areas of teeth nos. 20, 21 and 22, along with the extraction site of tooth no. 23.

nos. 20, 21 and 22 and facial bone loss associated with tooth no. 20. Two weeks after extraction of teeth nos. 21 and 22, her previous oral surgeon documented that the patient had delayed healing of all three extraction sites and exhibited exposed necrotic bone in the extraction sites. The patient was re-examined three weeks later, with no improvement in her condition.

Three months before visiting our office, the patient had discontinued using the intravenous (IV) bisphosphonate drug, zoledronate (Zometa, Novartis Pharmaceuticals, East Hanover, N.J.), by order of her oncologist. She had been taking 4 milligrams monthly for treatment of metastatic breast cancer. The patient began the bisphosphonate therapy three months after being diagnosed with breast cancer. In addition to metastatic breast cancer, which was diagnosed two years before she came to our office, the patient had, according to her medical history, congestive heart failure (CHF),



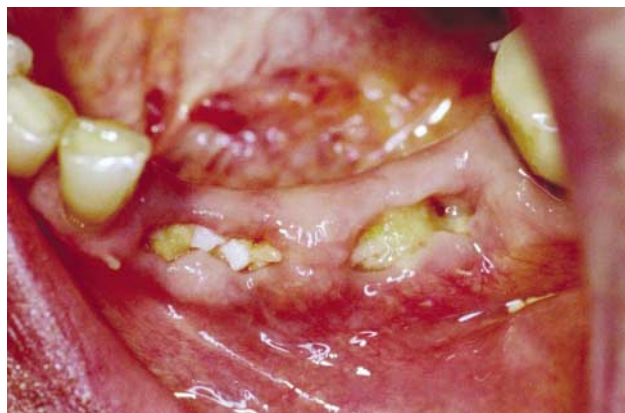**Figure 2.** Panoramic radiograph showing a diffuse sclerotic pattern around the extraction sites of teeth nos. 20, 21 and 22. Arrows indicate the areas of sclerotic bone.

hypertension and restrictive lung disease.

The patient also disclosed that she was taking exemestane to slow estrogen production associated with the metastasis. She also was receiving treatment with lisinopril and amlodipine besylate for CHF and hypertension, as well as a fentanyl transdermal system and hydrocodone for pain associated with the metastatic breast cancer. The patient reported no history of tobacco or alcohol use. In addition, she reported that she had not disclosed her bisphosphonate use to either her general dentist or previous oral surgeon until after the extractions had been performed. The patient did not think this medication was relevant to her current dental condition or treatment.

The physical and oral examination findings were unremarkable except for a mild swelling and exposed osseous tissue in the extraction site areas of teeth nos. 20, 21 and 22 (Figure 1). These extraction sites appeared to be nonhealing. On palpation by one of us (J.M.), tooth no. 23 was mobile and the patient experienced moderate pain; she also experienced mild pain along the extraction site areas of teeth nos. 20, 21 and 22. The differential diagnosis of the lesion included a fungal infection secondary to her immunocompromised status as well as osteoradionecrosis. The oral surgeon ruled out the latter because the patient reported that she had not received radiation therapy.

The oral surgeon obtained a panoramic radiograph, which revealed diffuse sclerosis of the cortical margins of the alveolar sockets along the



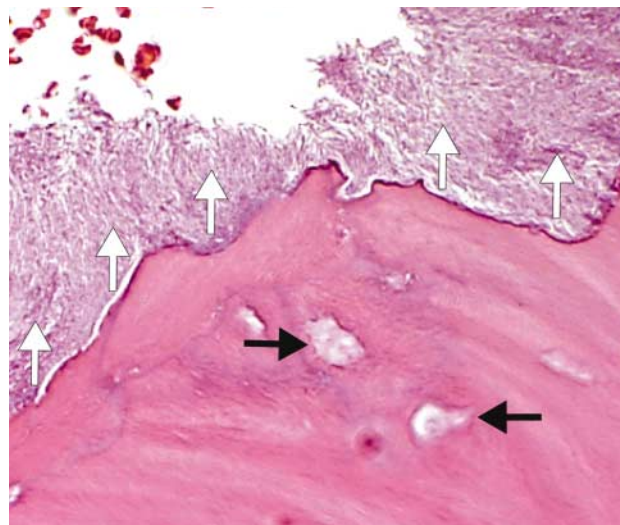
**Figure 4A. Surgical site two weeks after local débridement and extraction of tooth no. 23.**

area of the extraction sites. He found no evidence of bone deposition or trabecular pattern within the extraction sockets despite the length of time since the extractions had been performed (Figure 2).

The oral surgeon explored the patient's extraction sites and débrided and excised diseased and necrotic osseous and soft tissues. He noted purulent discharge associated with tooth no. 23, which necessitated its extraction, as well as further débridement of the alveolar socket. The oral surgeon removed necrotic alveolar bone until reaching what appeared to be bleeding vital osseous tissue. He irrigated the site, undermined the flap margins to gain tension-free flap closure and closed the operative site with multiple interrupted polypropylene sutures (Prolene, ETHICON, Somerville, N.J.) (Figure 3). The oral surgeon instructed the patient to use a chlorhexidine oral rinse three times a day and initiated antibiotic treatment with 500 mg of penicillin VK four times a day.

**Microscopic evaluation.** We submitted the excised tissues for microscopic evaluation, which revealed the presence of hard tissue composed of necrotic bone spicules with bacterial colonization and interspersed acute and chronic inflammatory cells. In addition, we noted fragments of soft tissue consisting of proliferating stratified squamous epithelium with arcading rete pegs and neutrophilic exocytosis. The subjacent fibrous connective tissue revealed the presence of patches of plasma cells, interspersed neutrophils and surgical hemorrhage. The microscopic diagnosis was infected bone sequestrum consistent with osteomyelitis.

**Follow-up.** The patient returned to our office two weeks later for follow-up. The oral exami-



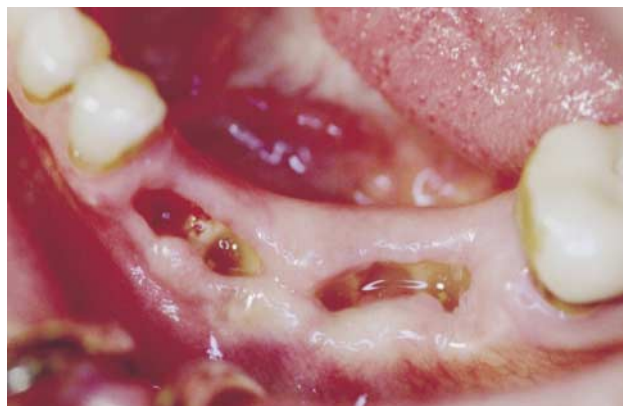**Figure 4B. High-magnification view of the necrotic bone showing typical empty lacunae (black arrows). In addition, an irregular peripheral resorption conspicuously absent of osteoclasts and a dense superficial bacterial colonization composed mainly of filamentous microorganisms are seen in this field (white arrows) (hematoxylin-eosin stain, original magnification x200).**

nation revealed evidence of soft-tissue breakdown of the flap closure, with visible necrotic alveolar bone (Figure 4A). The oral surgeon débrided the site again until he observed viable bleeding bone; he submitted the tissue for microscopic examination. The specimen exhibited microscopic features virtually identical to those seen in the first biopsy specimen (Figure 4B). However, in one section, a bacterial colony exhibited features reminiscent of actinomycosis. There was, however, no unambiguous clinical or microscopic evidence of this disease.

Six weeks after the patient's initial visit to our office (Figure 5), the surgical site showed only minimal improvement with regard to healing but good resolution of the previous pain and swelling. We decided that the next course of treatment was to be conservative, with continued chlorhexidine use and long-term antibiotic therapy with penicillin VK at a dosage of 1 gram every six hours until symptoms subsided. We would perform further surgical débridement only if needed to treat recurrent local symptomatic pain. We also would provide antibiotic coverage on reappearance of the osteonecrosis. The oral surgeon advised the patient to follow up with recall appointments every three weeks after the last débridement.

Because of the patient's refractory bone pain, her oncologist reinstated the zoledronate treatment as part of her chemotherapy regimen. She





**Figure 5. Surgical site six weeks after multiple débridements showing exposed alveolar bone with some evidence of osteonecrosis.**

experienced good relief of the systemic bone pain after reinstatement of the drug therapy. Unfortunately, shortly after her last visit to our office, the patient died of metastatic breast carcinoma.

## DISCUSSION

**Possible mechanisms of action.** The use of bisphosphonates in the treatment of systemic bone diseases and metastatic cancers is becoming more common.<sup>19</sup> Although their mechanisms of action still are being elucidated, these drugs are understood to hinder the resorption of bone by inhibition of osteoclastic activity. Hughes and colleagues<sup>20,21</sup> described inhibition of osteoclast development from monocytes, increased osteoclastic apoptosis (programmed cell death) and prevention of osteoclastic development from bone marrow precursors. Sato and Grasser<sup>22</sup> reported a reduction in osteoclastic activity through the effect of bisphosphonate on the cytoskeletal structure of the cell. Teronen and colleagues<sup>23</sup> presented an alternative theory of bisphosphonate activity through its effects on down-regulation of matrix metalloproteinases. Vitte and colleagues<sup>24</sup> observed stimulation of osteoclastic inhibitory factor synthesis by osteoblasts. Others<sup>25</sup> have detected an antiangiogenic effect associated with bisphosphonates, and some evidence shows that the drugs may have a direct antitumor effect by inducing apoptosis of tumor cells.<sup>5</sup>

The table lists bisphosphonate medications currently approved for use in the United States. This class of drugs includes both IV and oral forms, but it is primarily the parenteral (IV) forms that have been associated with osteonecrosis of the jaws. However, this phenomenon has been reported to occur in patients using oral

**TABLE**

## BISPHOSPHONATE DRUGS AVAILABLE IN THE UNITED STATES, MAY 2005.

GENERIC DRUG NAME (TRADE NAME AND MANUFACTURER)	ROUTE OF ADMINISTRATION
<b>Pamidronate (Aredia, Novartis Pharmaceuticals, East Hanover, N.J.)</b>	Parenteral
<b>Zoledronate (Zometa, Novartis Pharmaceuticals)</b>	Parenteral
<b>Etidronate (Didronel, Procter &amp; Gamble Pharmaceuticals, Cincinnati)</b>	Oral, parenteral
<b>Risedronate (Actonel, Procter &amp; Gamble Pharmaceuticals)</b>	Oral
<b>Tiludronate (Skelid, Sanofi Pharmaceuticals, New York City)</b>	Oral
<b>Alendronate (Fosamax, Merck &amp; Whitehouse Station, N.J.)</b>	Oral
<b>Ibandronate (Boniva, Hoffmann-La Roche, Nutley, N.J.)</b>	Oral

forms of the drugs on a long-term basis.<sup>8,26</sup>

Patients receiving treatment with these medications have been found to be at risk of experiencing delayed healing from tooth extractions and spontaneous soft-tissue breakdown leading to intraoral bone exposure. The appearance of bisphosphonate-associated osteonecrosis is identical to the appearance of osteoradionecrosis in patients who develop it after undergoing head and neck irradiation.<sup>15</sup> The reason for this complication is not clear, but treatment of necrotic bone in intraoral areas is problematic. This clinical quandary is similar to that seen in osteopetrosis and phosphorus poisoning (so-called “phossy jaw”),<sup>27</sup> two recognized entities with difficult treatment issues.

Unlike osteoradionecrosis, bisphosphonate-associated osteonecrosis is systemic rather than localized, and it does not appear to be associated with decreased vascularity. Therefore, hyperbaric oxygen therapy, which has been shown to be helpful in treating patients with osteoradionecrosis, may not be helpful in these cases. There does, however, seem to be an association with bacterial infection in most patients who have bisphosphonate-associated osteonecrosis. We also need to point out that most patients who develop this condition are immunocompromised by virtue of metastatic cancer, and they are exposed to

other medications known to be associated with osteonecrosis of the jaws (for example, chemotherapeutic agents and corticosteroids).

**Symptoms.** Symptoms may be negligible, mild or severe. The most severe cases can cause intense pain, extensive sequestration of bone and sinus tracts that drain to the skin surface.<sup>10,27</sup> Patients with advanced disease may require surgical intervention that is beyond the scope of practice of most general dentists.

It is important for dentists to be aware of possible poor surgical outcomes in patients receiving bisphosphonate treatment and to recognize poor healing responses early. They should consider referring these patients to an oral and maxillofacial surgeon for even the most routine dental extraction. Although clinicians might consider removing bisphosphonate therapy from the patient's chemotherapy regimen, the patient's oncologist and other members of the medical team may not advise doing so owing to the profound beneficial effects that these drugs have on the patient's quality of life. Furthermore, no strong evidence exists that discontinuation of bisphosphonate therapy will have any significant impact on surgical outcomes, because measurable levels of bisphosphonates may persist in bone for up to 12 years after cessation of the therapy.<sup>28</sup>

**Treatment.** Patients with asymptomatic exposed bone are best treated with systemic antibiotics (such as penicillin or clindamycin), an oral antimicrobial rinse (such as chlorhexidine gluconate) and, most importantly, close follow-up.<sup>15,27</sup> Attempts at extensive débridement and local flap closure often seem to be unsuccessful, and they may result in even larger areas of exposed and painful infected bone. Patients with draining sinuses, extensive areas of necrotic bone or large sequestrae may require more extensive surgical procedures, and their treatment course typically is protracted. In extensive cases in which purulent exudates or sinus tracts are visualized, culture and microbial sensitivity testing may be warranted. For many patients, complete healing may not occur, but alleviation of painful symptoms can help make the condition tolerable.<sup>27</sup>

By assisting in the pretreatment phase of a patient's chemotherapy, the dentist may have the most significant impact of all members of the health care team in preventing complications associated with bisphosphonate use. Crucial to the patient's overall well-being are a thorough dental

examination and control of existing oral disease, especially dental caries, periodontal lesions and periapical/periradicular disease, as well as the elimination of mucosal irritating factors such as a denture flange contacting mandibular or palatal tori. Untreated dental disease may progress rapidly during chemotherapy as the patient becomes increasingly immunocompromised and susceptible to otherwise harmless infections.

The dentist's role as part of the medical treatment team is particularly important to enhancing the quality of life for these often very ill patients. Therefore, clinicians should conduct a thorough oral examination before patients begin any parenteral bisphosphonate treatment so that they can perform any necessary invasive dental procedure or remove any mucosal irritating factors.

## CONCLUSION

Bisphosphonate therapy can be a key component of a patient's chemotherapy regimen. Use of bisphosphonates is on the rise and the beneficial effects of alleviating bone pain associated with an array of disorders are clear. The dentist must educate the patient preparing to undergo any chemotherapy regimen about the possible dental side effects of bisphosphonate therapy and take the necessary preventive measures to keep potential side effects to a minimum. Dentists should consider referring these patients to a specialist for even the simplest of extractions or other surgical dental procedures so that he or she can manage the adverse effects that may arise from oral surgical treatment. When possible, these treatments should be performed at least one month before initiation of any bisphosphonate therapy.

Although no definitive treatment exists for bisphosphonate-associated osteonecrosis, clinicians can best provide symptomatic and palliative care with systemic antibiotics (such as penicillin or clindamycin) and an oral antimicrobial rinse (such as chlorhexidine gluconate), possibly for the patient's lifetime. Close follow-up every three to four months is imperative to track the progress of the disease and to be on the lookout for any side effects that may arise from bisphosphonate therapy. ■

Mr. Markiewicz is a third-year predoctoral student, University at Buffalo School of Dental Medicine. Address reprint requests to Mr. Markiewicz, 6490 Main Street, Suite 3, Williamsville, N.Y. 14221, e-mail "mrm25@buffalo.edu".

Dr. Margarone is a clinical assistant professor, Department of Oral and Maxillofacial Surgery, University at Buffalo School of Dental Medi-

cine, Buffalo, N.Y., and has a practice limited to oral and maxillofacial surgery in Williamsville, N.Y.

Dr. Campbell is an associate professor and residency director, Department of Oral and Maxillofacial Surgery, University at Buffalo School of Dental Medicine, Buffalo, N.Y.

Dr. Aguirre is a professor, Department of Oral Diagnostic Sciences, and the director of the Advanced Oral and Maxillofacial Pathology program, University at Buffalo School of Dental Medicine, Buffalo, N.Y.

The authors thank Samuel Goodloe III, D.D.S., M.D., Tracey Abram, Christine Conrad, Mary Ilecki, Diane Miller and Laura Redner for their assistance in the preparation of this article.

1. Aparicio A, Gardner A, Tu Y, Savage A, Berenson J, Lichtenstein A. In vitro cytoreductive effects on multiple myeloma cells induced by bisphosphonates. *Leukemia* 1998;12:220-9.
2. Gralow J. Evolving role of bisphosphonates in women undergoing treatment for localized and advanced breast cancer. *Clin Breast Cancer* 2005;5(supplement 2):S54-62.
3. Kumar A, Loughran T, Alsina M, Durie BG, Djulbegovic B. Management of multiple myeloma: a systematic review and critical appraisal of published studies. *Lancet Oncol* 2003;4:293-304.
4. Lee MV, Fong EM, Singer FR, Guenette RS. Bisphosphonate treatment inhibits the growth of prostate cancer cells. *Cancer Res* 2001;61:2602-8.
5. Yoneda T, Hashimoto N, Hiraga T. Bisphosphonate actions on cancer. *Calcif Tissue Int* 2003;73:315-8.
6. Santini D, Fratto ME, Vincenzi B, La Cesa A, Dianzani C, Tonini G. Bisphosphonate effects in cancer and inflammatory diseases: in vitro and in vivo modulation of cytokine activities. *BioDrugs* 2004;18:269-78.
7. Tarassoff P, Csermak K. Avascular necrosis of the jaws: risk factors in metastatic cancer patients. *J Oral Maxillofac Surg* 2003;61:1238-9.
8. Migliorati CA. Bisphosphonates and oral cavity avascular bone necrosis. *J Clin Oncol* 2003;21:4253-4.
9. Carter GD, Goss AN. Bisphosphonates and avascular necrosis of the jaws. *Aust Dent J* 2003;48:268.
10. Ruggiero SL, Mehrotra B, Rosenberg TJ, Engroff SL. Osteonecrosis of the jaws associated with the use of bisphosphonates: a review of 63 cases. *J Oral Maxillofac Surg* 2004;62:527-34.
11. Schwartz HC. Osteonecrosis of the jaws: a complication of cancer chemotherapy. *Head Neck Surg* 1982;4:251-3.
12. Greenberg MS. Intravenous bisphosphonates and osteonecrosis. *Oral Surg Oral Med Oral Pathol Oral Radiol Endod* 2004;98:259-60.

13. Sung EC, Chan SM, Sakurai K, Chung E. Osteonecrosis of the maxilla as a complication to chemotherapy: a case report. *Spec Care Dentist* 2002;22(4):142-6.

14. Melo MD, Obeid G. Osteonecrosis of the maxilla in a patient with a history of bisphosphonate therapy. *J Can Dent Assoc* 2005;71(2):111-3.

15. Marx RE. Pamidronate (Aredia) and zoledronate (Zometa) induced avascular necrosis of the jaws: a growing epidemic. *J Oral Maxillofac Surg* 2003;61:1115-7.

16. Wang J, Goodger NM, Pogrel MA. Osteonecrosis of the jaws associated with cancer chemotherapy. *J Oral Maxillofac Surg* 2003;61:1104-7.

17. Bagan JV, Murillo J, Jimenez Y, et al. Avascular jaw osteonecrosis in oncology: International Bone and Cancer Study Group. *J Oral Pathol Med* 2005;34(2):120-3.

18. Zometa (zoledronic acid for injection). Rockville, Md.: U.S. Food and Drug Administration. Available at: "www.fda.gov/cder/foi/label/2002/213861bl.pdf". Accessed Nov. 1, 2005.

19. Body JJ, Bartl R, Burckhardt P, et al. Current use of bisphosphonates in oncology: International Bone and Cancer Study Group. *J Clin Oncol* 1998;16:3890-9.

20. Hughes DE, Wright KR, Uy HL, et al. Bisphosphonates promote apoptosis in murine osteoclasts in vitro and in vivo. *J Bone Miner Res* 1995;10:1478-87.

21. Hughes DE, MacDonald BR, Russell RG, Gowen M. Inhibition of osteoclast-like cell formation by bisphosphonates in long-term cultures of human bone marrow. *J Clin Invest* 1989;83:1930-5.

22. Sato M, Grasser W. Effects of bisphosphonates on isolated rat osteoclasts as examined by reflected light microscopy. *J Bone Miner Res* 1990;5(1):31-40.

23. Teronen O, Laitinen M, Salo T, et al. Inhibition of matrix metalloproteinases by bisphosphonates may in part explain their effects in the treatment of multiple myeloma. *Blood* 2000;96:4006-7.

24. Vitte C, Fleisch H, Guenther HL. Bisphosphonates induce osteoblasts to secrete an inhibitor of osteoclast-mediated resorption. *Endocrinology* 1996;137:2324-33.

25. Santini D, Vincenzi B, Avvisati G, et al. Pamidronate induces modifications of circulating angiogenic factors in cancer patients. *Clin Cancer Res* 2002;8:1080-4.

26. Migliorati CA, Schubert MM, Peterson DE, Seneda LM. Bisphosphonate-associated osteonecrosis of mandibular and maxillary bone: an emerging oral complication of supportive cancer therapy. *Cancer* 2005;104(1):83-93.

27. Hellstein JW, Marek CL. Bisphosphonate osteochemonecrosis (bis-phossy jaw): is this phossy jaw of the 21st century? *J Oral Maxillofac Surg* 2005;63:682-9.

28. Lin JH, Russell G, Gertz B. Pharmacokinetics of alendronate: an overview. *Int J Clin Pract Suppl* 1999;101:18-26.